



Theriogenology Question of the Month

History

An 8-year-old Quarter Horse–Paint mare was examined at the University of Pennsylvania New Bolton Center Veterinary Medical Teaching Hospital because of moderate colic and stranguria of 12 hours' duration. Results of examination of the mare at the farm of origin were suggestive of urinary tract obstruction on the basis of a possibly distended bladder and inability to catheterize the urethra. The mare had been purchased 5 weeks previously; the mare's medical history prior to that time was unknown.

Physical examination revealed that the mare was bright, alert, and responsive. Rectal temperature, heart rate, and respiration rate and results of analysis of a fluid sample obtained by use of abdominocentesis, a CBC, and plasma biochemical analysis were within reference ranges.^a Fibrinogen concentration was mildly high (666 mg/dL; reference range, 150 to 375 mg/dL). The mare was administered flunixin meglumine^b (1 mg/kg [0.45 mg/lb], IV, q 12 h).

The urethra was catheterized, but only a small volume of urine was obtained. Inadvertently, the urine sample was not submitted for urinalysis or microbial culture. Subsequent cystoscopic examination revealed extramural compression of the dorsal bladder wall and urethral inflammation, the latter of which may have been a result of the preceding catheterization procedures.

Initial transrectal palpation and ultrasonography revealed a distended viscus (> 15 cm in diameter) within the caudal portion of the abdomen; the viscus did not involve the gastrointestinal tract. Additional transrectal ultrasonographic examination with a 7.5-MHz linear-array transducer^c at a depth of 8 cm was performed by the reproductive service. That examination identified the viscus as fluid distention of the uterus and vagina and a portion of the vestibule (Figure 1). An echogenic structure, most consistent with a CH, was detected in the left ovary during transrectal ultrasonography. The mare also displayed signs of pain when the left ovary was manipulated. The right ovary contained multiple small follicles. In addition, the bladder appeared intact and contained only a small amount of urine. Manual or visual vaginal examination was not performed because a mass covered with normal-appearing mucosa was located in the area of the vestibulovaginal junction. The mare was admitted for additional evaluation and treatment.

This report was submitted by Gina G. Tranquillo, BS; Audrey A. Kelleman, DVM, DACT; and Patricia L. Sertich, MS, VMD, DACT; from the Section of Reproductive Studies, New Bolton Center, School of Veterinary Medicine, University of Pennsylvania, Kennett Square, PA 19348.

Address correspondence to Dr. Kelleman (kelleman@vet.upenn.edu).

ABBREVIATIONS

CH	Corpus hemorrhagicum
CL	Corpus luteum

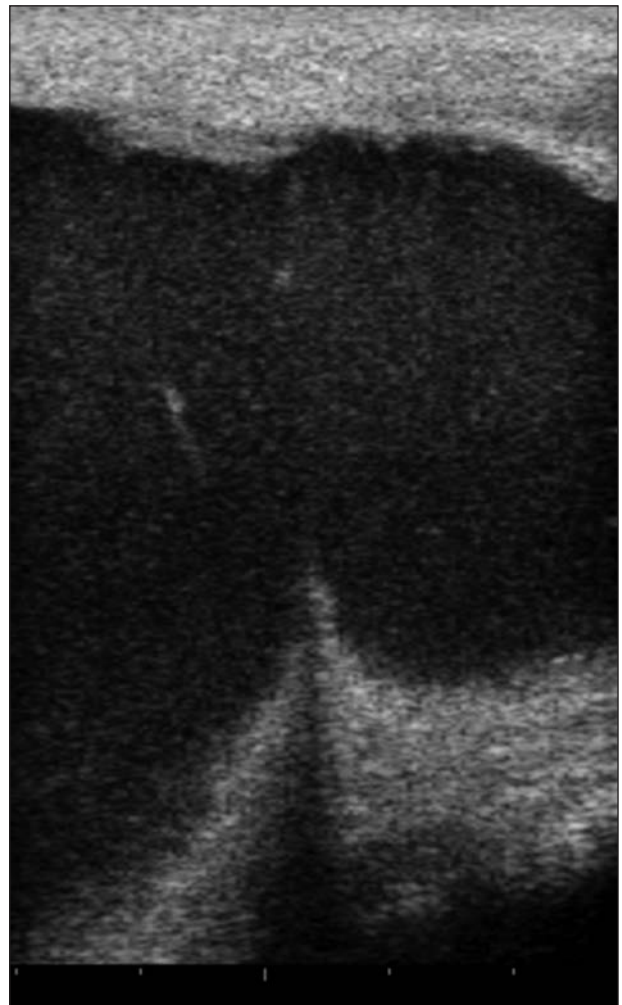

Figure 1—Ultrasonographic view of the caudal portion of the vagina and vestibule of an 8-year-old Quarter Horse–Paint mare examined because of colic and stranguria of 12 hours' duration. The ultrasonogram was obtained during transrectal ultrasonographic examination with a 7.5-MHz linear-array transducer^c at a depth of 8 cm. Cranial is to the left side of the ultrasonogram, and caudal is to the right. Notice the vestibulovaginal fold and that the vagina and vestibule appear to be distended with hyperechoic fluid. The bladder is not visible. Tick marks at the bottom of the image are at intervals of 1 cm.

Question

What are the differential diagnoses for uterine distention attributable to fluid accumulation in this mare?
Please turn the page.

Answer

Pregnancy, pyometra, mucometra, hydrometra, hemorrhage, and urometra.

Results

On the day after admission, the mare was evaluated more extensively. The mammary glands were small, and no secretions were evident, which were consistent with a nonlactating mare. The perineum was incompetent; the vulvar lips were asymmetric, and the left labia were recessed and irregularly shaped (Figure 2). The clitoris was normal in appearance, but the vestibular mucosa was edematous.

Transrectal palpation did not reveal abnormalities of the gastrointestinal tract. All organs were palpably normal with regard to position, texture, and size. Further transrectal palpation revealed a firm, distended vagina, vestibule, and cervix. Transrectal ultrasonography revealed an 8-mm-thick hyperechoic area in the vestibule that extended cranially and ventrally toward the urethral sphincter; this was identified as an adhesion. Manual and visual vaginal examinations revealed a complete adhesion near the vestibulovaginal junction. Fluid contained within the adhesion caused the area to bulge into the vestibule. It was determined that the mucosa-covered mass was the fluid-filled reproductive tract enclosed by this adhesion (Figure 1), which thus created a mass effect. The stranguria had lessened overnight; thus, further evaluation of the urinary tract was not performed.

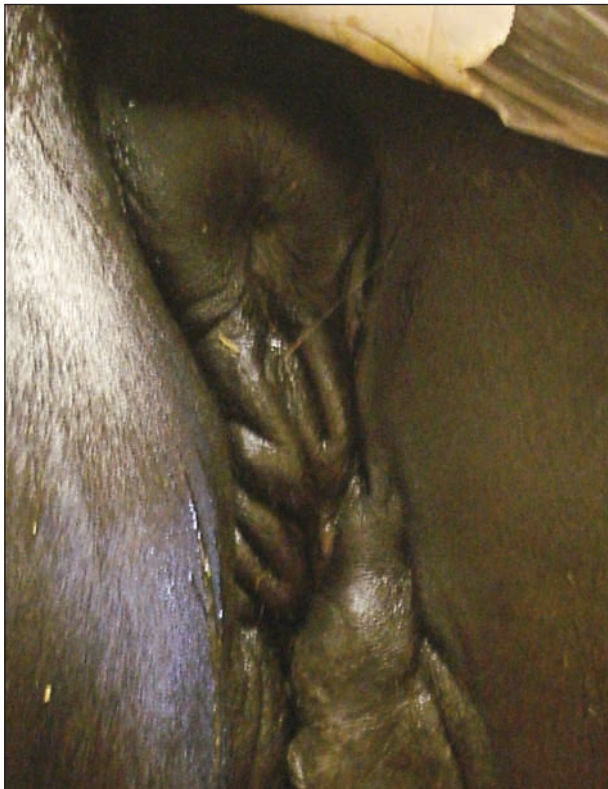

Figure 2—Photograph of the abnormal perineum of an 8-year-old Quarter Horse–Paint mare with a fluid-filled viscous mass in the caudal portion of the abdomen, vagina, and vestibule.

Transabdominal ultrasonography with a 4.5-MHz curvilinear transducer^d at a depth of 28.5 cm revealed distended uterine horns. Diameter of the left and right uterine horn was 18.52 and 23.09 cm, respectively. The uterine horns extended bilaterally and caudally into the inguinal region. Echogenicity of the fluid within the lumens of the uterine horns increased ventrally, with the most echogenic material at the ventral aspect and hypoechoic fluid at the dorsal aspect (Figure 3). Thickness of the uterine wall (2.9 to 5.3 mm) was not influenced by location (ie, dorsal vs ventral in the uterine horn). Uterine size was consistent with a pregnancy of approximately 100 days,¹ but there was no evidence of a fetus or fetal remnants. In addition, free abdominal fluid was not detected.

The vestibular adhesion was manually ruptured, and an estimated 15 L of light-brown translucent malodorous fluid was expelled from the genital tract of the mare. Toward the end of the expulsion, the effluent became progressively more opaque and white. Aerobic microbial culture of a sample of this fluid yielded *β-Streptococcus* spp group C. After fluid evacuation, a vestibular stricture prevented the examiner from being able to manually perform a thorough evaluation of the cervix and uterus. The uterus was lavaged with 12 L of sterile saline (0.9% NaCl) solution, and the mare was administered oxytocin^e (10 U, IV). After uterine lavage and administration of the oxytocin, the diameter of the left and right uterine horns was 5.4 and 2.8 cm, respectively. The definitive diagnosis was pyometra attributable to transluminal vestibular adhesion.

Twenty-four hours after rupture of the adhesion and uterine evacuation, the mare was reexamined. Normal-appearing urination was observed; thus, the stranguria had resolved. Transrectal palpation and ultrasonography revealed that the left ovary contained a CL. In addition, the cervix did not have a palpably discernable tubular shape as would be expected in di-

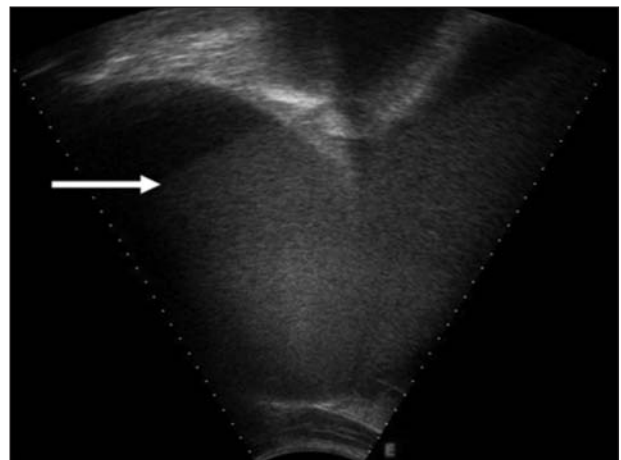


Figure 3—Ultrasonographic view of the left lateral inguinal region of the mare. The ultrasonogram was obtained during transcutaneous ultrasonographic examination with a 4.5-MHz curvilinear transducer^d at a depth of 28.5 cm. Because of settling of particulate matter in the intrauterine fluid, there is an increase in echogenicity ventrally and a decrease in echogenicity dorsally, and the interface between these 2 echogenic regions is evident (arrow). This settling of particulate matter and ultrasonographic image is characteristic of pyometra. Tick marks on the sides of the image are at intervals of 1 cm.

estrus; however, the uterus was contracted and had excellent tone. The uterus was lavaged with 6 L of sterile saline solution and 480 mL of hydrogen peroxide. Because the fluid that was expelled from the uterus the previous day was malodorous, it may have contained anaerobic bacteria. Therefore, hydrogen peroxide was included in the lavage to oxygenate, albeit temporarily, the intrauterine environment. An ointment containing nystatin, neomycin sulfate, thioestrepton, and triamcinolone acetonide^f was then applied topically to the vestibule. As indicated by the CL, the mare was not in estrus and the estrus behavior of frequently posturing to urinate had subsided. In addition, the potential mechanical irritation caused by the mass bulging into the vestibule had been alleviated.

Discussion

Signs of abdominal discomfort (ie, colic) were not directly related to the gastrointestinal tract or the urinary tract in the mare reported here. The reproductive tract was the most likely source of the signs of abdominal pain in this mare, specifically attributable to the left ovary or the uterus. Ovulation as a source of colic was possible given the CH in the left ovary; however, abdominal pain as a result of uterine distention from the pyometra was considered the most likely cause. The asymmetric incompetent perineum was likely a result of trauma during a previous parturition. Such trauma may have caused the vestibular adhesion. Another possible cause of the adhesion was mucosal exposure to irritant substances. In the experience of one of the authors (AAK), standard povidone-iodine soaps or solutions in some sensitive mares can cause severe inflammation of the perineum and vestibule. The pyometra probably then resulted from a lack of drainage of the genital tract. The distended uterus and vagina, which compressed the bladder and urethra, respectively, may have caused the stranguria. In addition, during the most recent estrus, the mare may have had vestibular irritation from an increased frequency of posturing to urinate and mechanical irritation from the bulging vestibular mass, both of which may have contributed to the stranguria. Finally, frequent posturing to urinate and eversion of the clitoris are typical behaviors for a mare in estrus and may have been interpreted as stranguria by farm personnel.

Although not detected in this particular mare, another uncommon differential diagnosis for abdominal discomfort related to distention of the genital tract is pneumometra. This condition may be seen in estrous or anestrus mares with an incompetent perineum and vestibulovaginal junction, both of which do not close and seal properly and thus allow air to pass through the relaxed cervix and into the uterus.² Pain is a result of increased pressure in the uterus. In the experience of one of the authors (PLS), mares prone to pneumometra may have chronic intermittent colic. Vulvoplasty is therapeutic. Standard treatments for colic will not eliminate the underlying problem of pneumometra.

Pyometra in mares can develop when drainage of uterine fluid is hindered because of cervical incompetence, which results in intraluminal accumulation of

purulent or mucopurulent fluid.³ In such cases, the incompetent cervix does not open properly. The term incompetent is used to denote abnormalities of function and may be used to indicate failure to open or failure to close properly. These abnormalities may be a consequence of trauma, such as that resulting from dystocia. Furthermore, it has been theorized⁴ that decreased myoelectrical activity and motility are compounding factors in uterine accumulation of fluid. In other instances, purulent material may collect without detectable occlusion of the cervix.³ Failure of mechanical clearance of the uterus is responsible for most of the cases of pyometra in mares. The mare described here was unique in that the genital tract was occluded near the vestibulovaginal junction and not at the cervix.

Mares with pyometra generally do not display clinical signs of systemic disease,^{3,5} although signs of depression, weight loss, and colic have been reported.⁶ The mare described here displayed signs of moderate abdominal discomfort and stranguria and had a mild increase in fibrinogen concentration. Intermittent discharge from the vulva when a relaxed cervix allows drainage of purulent fluid is often a primary clinical sign in a mare with pyometra.⁵ In mares with complete cervical adhesion, there will be no discharge from the vulva. In contrast, in bitches with a closed-cervix pyometra, anorexia, signs of depression, abdominal distention, polydipsia, and vomiting can manifest.⁷ In cows, pyometra is defined as fluid accumulation within the lumen of at least 1 uterine horn and a progesterone-producing CL; however, affected cows may or may not have discharge from the vulva.⁸ Cows with pyometra do not display systemic signs of illness.

The role of progesterone in pyometra varies among species. In mares, a CL is not required, but progesterone will contribute by decreasing uterine immune responses and mechanically closing the cervix. In contrast, cows that develop pyometra typically have early postpartum ovulation coupled with a high postpartum pathogenic load of microorganisms in the uterus.⁸ Cows and bitches under progesterone influence by a CL are more susceptible to uterine infection than those not under progesterone influence. Therefore, cows and bitches require a CL and progesterone to create an environment necessary for development of a pyometra. This is in contrast to mares, in which cervical incompetence is considered to be the primary factor in development of pyometra.

Similar to the situation in cows, mares may have a prolonged diestrus as a result of persistent luteal tissue present in animals with pyometra.^{3,8} Progesterone will inhibit estrus behaviors; thus, cows and mares with pyometra may not have typical interestrus intervals. The accumulation of purulent fluid and resulting uterine distention can cause damage or destruction of the endometrium in mares. The endometrium is the site of production of prostaglandin, which causes luteolysis. Damaged endometrium in mares with pyometra may not produce sufficient amounts of prostaglandin; thus, a prolonged diestrus and progesterone dominance may result.^{3,5} In contrast to mares with pyometra, mares with endometritis may have abnormally short interestrus intervals. This is attributable to the release of prostaglan-

din from the inflamed endometrium, with subsequent luteolysis and return to estrus.

Pyometra may be considered a separate disease entity when compared with endometritis or metritis. Mares with endometritis are not systemically ill, and only the endometrium is affected. Endometritis may be caused by infection or sterile inflammation. Such inflammation often develops after breeding and can be associated with bacteria. Irritant substances (such as air or urine) can also cause inflammation. In addition, endometritis is a common problem, whereas pyometra develops less frequently. In contrast to endometritis, metritis is inflammation or infection of the endometrium and myometrium. Metritis causes systemic illness with signs of depression, pyrexia, inappetence, endotoxemia, and laminitis. It is most common in postpartum mares, especially those with retained fetal membranes.⁹

It was expected that the mare described here would have chronic pyometra, and curative ovariohysterectomy⁶ was suggested to the owner. Short of surgical intervention (ie, ovariohysterectomy), chronic pyometra is managed and not cured; therefore, periodic palliative treatment is warranted. Management is aimed at assisting the uterus in physically clearing inflammatory products through the use of high-volume uterine lavage and administration of ecbolics. In addition, antimicrobial culture and susceptibility testing of uterine fluid can be used to facilitate treatment.⁵ Local intrauterine administration of appropriate antimicrobials can cause a short-term decrease in the bacterial load of the uterus and therefore may be warranted.

Prognosis for fertility in a mare with pyometra is usually poor to grave, depending on the severity of pathological changes to the reproductive tract. Recurrence of pyometra is common. If the owners had desired a more definitive prognosis for the future fertility of this mare, additional diagnostic evaluation would have been warranted. Histologic examination of endometrial biopsy specimens can provide detailed information about health of the endometrium and would also give an indication of the mare's ability to carry a foal for a full-term gestation. Because the cervix could not be assessed manually as a result of the vestibular stricture, endoscopic examination during both estrus and diestrus to evaluate cervical incompetency would be warranted.⁵ In addition, the vestibular stricture would likely require surgical correction to allow birth of a foal per vaginam.

Although a mare with pyometra may have a grave prognosis for carrying a foal to term, the use of new reproductive technologies could allow this mare to produce offspring. Oocyte transfer would be an option. In this procedure, a mature preovulatory oocyte is retrieved via transvaginal follicular aspiration. This

oocyte is then transferred into the oviduct of an inseminated anovulatory recipient mare; thus, pregnancy may be achieved. Cloning of the mare would be another option.

The mare described here illustrated the importance of considering differential diagnoses associated with the reproductive tract, despite initial clinical signs attributed to the gastrointestinal and urinary systems.

Outcome

Approximately 1 year later, the owner was contacted via telephone to obtain follow-up information. The mare had not had any additional signs of colic, vulvar discharge, or stranguria. Because the mare remained clinically normal, further examinations of the reproductive tract to determine a cause for colic had not been performed. The mare had been used for pleasure riding and was performing adequately.

-
- Clinical Pathology Laboratory, College of Veterinary Medicine, University of Pennsylvania, Kennett Square, Pa.
 - Banamine, Schering-Plough Animal Health, Union, NJ.
 - MyLab30 Vet, Universal Medical System Inc, Bedford Hills, NY.
 - Technos2, Biosound ESAOTE, Indianapolis, Ind.
 - Oxytocin, Bimeda-MTC Animal Health Inc, Cambridge, ON, Canada.
 - Animax ointment, Pharmaderm Animal Health, Melville, NY.
-

References

- Roberts SJ. Pregnancy diagnosis—pregnancy diagnosis in the mare. In: Roberts SJ, ed. *Veterinary obstetrics and genital disease (theriogenology)*. 3rd ed. Woodstock, Vt: Published by the author, 1986;27.
- Threlfall WR. Pneumovagina/pneumouterus. In: Lavoie J-P, Hinchcliff KW, eds. *Blackwell's five-minute veterinary consult: equine*. 2nd ed. Ames, Iowa: Wiley-Blackwell, 2008;607.
- Hughes JP, Stabenfeldt GH, Kindahl H, et al. Pyometra in the mare. *J Reprod Fertil Suppl* 1979;(27):321–329.
- Nikolakopoulos E, Watson ED. Uterine contractility is necessary for the clearance of intrauterine fluid but not bacteria after bacterial infusion in the mare. *Theriogenology* 1999;52:413–423.
- Cadario ME. Pyometra. In: Lavoie J-P, Hinchcliff KW, eds. *Blackwell's five-minute veterinary consult: equine*. 2nd ed. Ames, Iowa: Wiley-Blackwell, 2008;652–653.
- Rötting AK, Freeman DE, Doyle AJ, et al. Total and partial ovariohysterectomy in seven mares. *Equine Vet J* 2004;36:29–33.
- Dow C. The cystic hyperplasia-pyometra complex in the bitch. *Vet Rec* 1958;70:1102–1108.
- Etherington WG, Christie KA, Walton JS, et al. Progesterone profiles in postpartum Holstein dairy cows as an aid in the study of retained fetal membranes, pyometra, and anestrus. *Theriogenology* 1991;35:731–746.
- Wolfsdorf K, Caudle AB. Inflammation of the tubular reproductive tract of the mare. In: Youngquist RS, Threlfall WR, eds. *Current therapy in large animal theriogenology*. 2nd ed. St Louis: Saunders Elsevier, 2007;158–167.